

## Gastric Cancer and Metastasis to the Brain

Julie E. York, MD, Jared Stringer, MS, Jaffer A. Ajani, MD,  
David M. Wildrick, PhD, and Ziya L. Gokaslan, MD

---

**Background:** Metastasis of gastric carcinoma to the brain is very uncommon. At The University of Texas M. D. Anderson Cancer Center (M. D. Anderson), less than 1% of patients with primary gastric carcinoma are found to have brain metastases. Little has been published regarding the evaluation and treatment of these patients. The purpose of this study was to review our experience with gastric cancer metastatic to the brain and to describe the efficacy of the treatment used.

**Methods:** Between 1957 and 1997, a total of 218,690 patients were seen for evaluation of malignant tumors at M. D. Anderson. Of these patients, 3320 (1.5%) had a diagnosis of gastric cancer; however, only 24 patients (0.7%) were found to have brain metastases on imaging studies or at autopsy. We performed a retrospective review of these 24 patients and divided them into three groups on the basis of the treatment they received.

**Results:** Group 1 included patients who received steroids alone (16 mg of dexamethasone, daily). Group 2 patients received 3000 cGy of whole-brain radiation therapy (WBRT) delivered in 10 fractions in addition to steroids. Group 3 patients were managed with surgical resection, WBRT, and steroids. There were 18 male and 6 female patients, with a median age of 53 years. The most common presenting symptoms were weakness, difficulty with balance, and headache. Of the 19 patients diagnosed antemortem, 11 patients developed neurological symptoms after the primary diagnosis of gastric carcinoma, whereas 8 patients developed neurological symptoms before the diagnosis of gastric cancer. Forty-five percent of patients had a single brain metastasis, whereas 55% had multiple lesions. All patients had systemic disease, with bone, liver, and lung involvement seen in 46%, 42%, and 29%, respectively. Nineteen of 24 patients received treatment after diagnosis of brain metastases. Four patients received steroids only (group 1), 11 patients received WBRT and steroids (group 2), and 4 patients were treated with surgery, WBRT, and steroids (group 3). Median survival was approximately 2 months for patients in groups 1 and 2, whereas group 3 patients had a median survival of slightly greater than 1 year.

**Conclusions:** Our results suggest that the overall prognosis of patients with brain metastases from gastric cancer is extremely poor (median survival, 9 weeks). WBRT, as an adjuvant to steroid treatment, was not effective in improving outcome in our series. In selected patients, most of whom were relatively young and had less advanced systemic disease, surgical resection followed by WBRT was associated with relatively long survival times (median survival, 54 weeks).

**Key Words:** Brain—Gastric cancer—Metastasis.

---

Gastric cancer represents a worldwide health concern. For 1996, the World Health Organization reported that gastric cancer was the second most commonly occurring cancer.<sup>1</sup> There were approximately 1,015,000 new cases

diagnosed, worldwide, producing 776,000 deaths during the same period.<sup>1</sup> In the United States, the American Cancer Society estimated that 22,600 new cases of gastric carcinoma would be diagnosed in 1998 with 13,700 resultant deaths.<sup>2</sup> This high mortality rate may reflect the difficulty in diagnosing gastric cancer before the patient develops advanced metastatic disease.<sup>3</sup> Stomach cancer may follow a complex course that involves metastasis to the brain, although this does not occur as commonly as with other cancers such as lung or breast carcinoma.<sup>4,5</sup> The purpose of this study was to review our past experience with brain metastases from gastric cancer and to

---

Received March 19, 1999; accepted August 10, 1999.

From the Departments of Neurosurgery (JEY, JS, DMW, ZLG) and Gastrointestinal Medical Oncology/Digestive Diseases (JAA), The University of Texas M. D. Anderson Cancer Center, Houston, Texas.

Address correspondence and reprint requests to: Ziya L. Gokaslan, MD, Department of Neurosurgery-64, The University of Texas M. D. Anderson Cancer Center, 1515 Holcombe Blvd., Houston, TX 77030. Fax: 713-794-4950.

evaluate the efficacy of various treatment modalities in terms of neurological status and overall survival.

## MATERIALS AND METHODS

During a 40-year period (March 1, 1957, to August 31, 1997), 3320 patients were treated for gastric cancer at The University of Texas M. D. Anderson Cancer Center (M. D. Anderson), and 24 of these patients were found to have brain metastases. A retrospective review of the patients' charts was performed to determine important clinical characteristics and to evaluate the role of various treatment options. Data were collected on patient demographics, clinical presentation, diagnosis, clinical course, treatment, and outcome.

The patients in this study were divided into three groups on the basis of the treatment they received (Table 1). Group 1 patients received steroids alone (16 mg of dexamethasone, daily). Group 2 patients received 3000 cGy of whole-brain radiation therapy (WBRT) delivered in 10 fractions, in addition to steroids. Group 3 patients were managed with surgical resection, WBRT, and steroids. The outcome of treatment was assessed by comparing the neurological status of each patient before treatment with his posttreatment neurological status 1 month after initiation of therapy. Survival time was defined as the interval between the diagnosis of brain metastasis and the time of death and was assessed using the Kaplan-Meier method.<sup>6</sup>

## RESULTS

### Clinical Characteristics

Twenty-four patients with histologically verified gastric cancer were diagnosed as having brain metastases between March 1, 1957, and August 31, 1997. Pathological examination demonstrated adenocarcinoma in 23 patients and leiomyosarcoma in one patient. There were 18 men (15 Caucasian, 3 Hispanic) and 6 women (4 Caucasian, 1 Hispanic, and 1 black). The patients ranged in age from 31 to 78 years, with a median age of 53 years. Patient characteristics are summarized in Table 2.

Sufficient information was available to determine the location of the primary tumor in 19 patients. The major-

ity of these patients were diagnosed by endoscopic biopsy. Ten patients were diagnosed with a primary tumor confined to the proximal stomach, four patients were found to have a primary tumor located in the mid stomach, and one patient had a primary tumor in the distal stomach. Two patients had a tumor located in both the proximal and mid stomach. One patient had adenocarcinoma in both the mid and distal stomach, and one patient had linitis plastica. Treatment of the primary tumor consisted of chemotherapy in all patients but one, radiation therapy in eight patients, and gastric resection in 10 patients.

Nineteen patients presented with neurological symptoms during the course of their disease, with eight of them presenting before the diagnosis of their primary cancer. The most common presenting symptoms were weakness (67%), headache (42%), balance/gait abnormalities (42%), and nausea/emesis (38%). Less common findings were papilledema (13%) and seizures (8%). The interval between the diagnosis of the primary gastric tumor and the onset of neurological symptoms was determined for 11 patients (mean, 9 months; range, 1–23 months). The interval was not determined for the others, either because they developed neurological symptoms before the diagnosis of their primary tumor (eight patients) or because they did not exhibit neurological symptoms before death (five patients).

The diagnosis of brain metastasis was made by computed tomography (CT) or magnetic resonance imaging studies in 15 patients, electroencephalography and brain scintigraphy in four patients, and at autopsy in five patients. Tumor location was determined in 22 patients. Fourteen patients had supratentorial lesions, three patients had infratentorial lesions, and five patients had both supratentorial and infratentorial lesions. The number of lesions was determined in 20 patients. Nine patients had a single lesion, whereas 11 had multiple lesions. Five of the 15 patients who had undergone imaging studies had brain tumors with surrounding edema, three patients had tumors producing a midline shift, and three had hydrocephalus.

Twenty-one patients were diagnosed as having systemic illness before death. Systemic illness was determined by the following procedures: abdominal CT scanning, bone scintigraphy, exploratory laparotomy, and biopsy. The other three patients were found to have systemic disease at autopsy. The most common sites of metastases in these patients were bone (46%), liver (42%), and lungs (29%).

**TABLE 1.** Treatment groups of patients with brain metastases from gastric cancer

Patient group	Treatment
Group 1	Steroids only
Group 2	WBRT and steroids
Group 3	Surgical resection, WBRT, and steroids

WBRT, whole-brain radiation therapy.

TABLE 2. Characteristics of patients with brain metastases from gastric cancer

Demographics			Clinical presentation				Primary tumor			Systemic Disease					Brain metastases			Results								
Pat. No.	Age	Sex	Race	Time (mo) <sup>a</sup>	H/ A	N/ V	Seizure	Balance/ gait	Weakness	Papill- edema	Disease	Chemo	XRT	Surgery	Lymph nodes			Lung	Supratentorial	Infratentorial	Single/ multiple	Treatment group #	Neurological status	Survival (wk)		
															Local	Distant	Bone									
1	78	M	C	22	Y	Y	N	N	Y	N	Y	N	Y	Y	N	Y	Y	N	N	Y	N	S	I	unchanged	11	
2	31	M	C	N/A <sup>b</sup>	N	N	N	N	Y	N	Y	N	N	N	Y	Y	Y	Y	Y	Y	Y	M	II	worse	6	
3	61	M	H	1	N	Y	N	N	Y	N	Y	N	Y	N	N	N	N	N	N	N	N	?	I	deceased	1	
4	43	M	H	10	Y	Y	N	N	Y	N	Y	N	Y	Y	N	N	N	N	N	N	N	M	III	improved	?	
5	59	M	C	3	Y	Y	N	Y	Y	N	Y	Y	Y	Y	N	Y	Y	Y	N	N	S	II	improved	21		
6	44	M	C	Autopsy	N	N	N	N	Y	N	Y	Y	Y	Y	N	Y	N	N	N	N	?	N/A	?	N/A	N/A	N/A
7	50	M	C	10	Y	N	N	N	N	N	Y	Y	Y	Y	N	Y	Y	Y	N	N	?	III	improved	22		
8	54	F	H	N/A <sup>b</sup>	N	Y	N	N	Y	Y	Y	Y	Y	N	N	Y	N	N	N	N	M	II	deceased	1		
9	58	M	C	N/A <sup>b</sup>	N	N	N	N	Y	Y	Y	Y	Y	Y	N	N	N	N	N	N	?	I	I	deceased	10	
10	61	M	C	Autopsy	N	N	N	N	Y	N	Y	Y	Y	Y	Y	Y	Y	Y	Y	Y	M	N/A	N/A	N/A	N/A	
11	58	M	C	1	Y	N	N	N	Y	N	Y	N	Y	Y	N	Y	Y	Y	Y	Y	N	M	II	worse	15	
12	40	M	C	Autopsy	N	N	Y	Y	Y	Y	Y	Y	Y	Y	N	Y	Y	Y	Y	N	N	M	N/A	N/A	N/A	N/A
13	51	F	C	23	N	N	N	N	Y	N	Y	N	Y	Y	N	N	N	N	N	N	N	S	II	deceased	3	
14	40	M	C	21	Y	N	N	Y	N	N	Y	N	Y	Y	N	Y	Y	Y	Y	Y	N	S	III	improved	54	
15	62	F	C	3	N	Y	N	Y	Y	Y	Y	Y	Y	Y	N	Y	Y	Y	Y	Y	M	II	deceased	4		
16	53	M	C	N/A <sup>b</sup>	Y	Y	N	Y	Y	N	Y	Y	Y	Y	N	N	N	N	N	N	Y	M	II	unchanged	10	
17	58	M	C	Autopsy	N	N	N	N	N	N	Y	Y	Y	Y	N	N	N	N	N	N	N	S	N/A	N/A	N/A	N/A
18	60	F	C	N/A <sup>b</sup>	Y	N	N	N	Y	N	Y	N	N	N	Y	Y	Y	Y	Y	Y	Y	M	II	unchanged	9	
19	66	F	C	Autopsy	N	N	N	N	N	N	Y	Y	Y	Y	N	Y	Y	Y	Y	Y	N	M	II	N/A	N/A	N/A
20	36	M	C	N/A <sup>b</sup>	N	N	N	N	N	N	N	Y	Y	Y	N	Y	Y	Y	Y	Y	N	S	I	deceased	4	
21	52	M	H	4	Y	Y	N	Y	Y	Y	Y	Y	Y	Y	N	Y	Y	Y	Y	Y	N	M	II	unchanged	5	
22	43	F	B	N/A <sup>b</sup>	Y	Y	N	Y	Y	N	Y	Y	Y	Y	N	N	N	N	N	N	N	M	II	unchanged	11	
23	44	M	C	N/A <sup>b</sup>	N	N	N	Y	Y	N	Y	Y	Y	Y	N	N	N	N	N	N	N	S	III	unchanged	83	
24	73	M	C	2	N	Y	N	Y	Y	N	Y	Y	Y	Y	N	Y	Y	Y	Y	Y	N	M	II	unchanged	48	

Autopsy, patients whose brain metastases were diagnosed at autopsy; Pat. No., patient number; Chemo, chemotherapy; XRT, radiation therapy; N/A, not applicable as disease was diagnosed at autopsy; H/A, headache; N/V, nausea and vomiting; C, Caucasian; B, black; H, Hispanic; ?, not determined.  
<sup>a</sup> Time interval between diagnosis of primary tumor and neurological presentation.  
<sup>b</sup> Patients who developed neurological symptoms before diagnosis of primary tumor.

## Treatment

Overall, the outcome of patients with brain metastases from gastric cancer was poor. Five patients were determined to have brain metastases at autopsy, whereas 19 patients were diagnosed as having them before death. The median survival time determined for these 19 patients was 2.4 months (range, 5 days to 19.2 months) after diagnosis, as shown in Fig. 1. The cause of death was documented for 14 patients. Twelve patients died as a result of progressive disease at the primary site or from complications owing to metastasis, whereas two patients died as a consequence of metastatic brain disease.

Four patients were treated with steroids alone. Their survival times ranged from 1 to 11 weeks (median, 7 weeks). Two patients were alive at the time of their 1-month follow-up appointment; both patients were neurologically unchanged relative to their preoperative status.

Eleven patients received 3000 cGy of whole-brain radiation delivered in 10 fractions, in conjunction with corticosteroids. Their survival times ranged from 1 to 21 weeks (median, 9 weeks). Of the eight patients alive at 1 month after treatment, one patient was neurologically improved, five patients were unchanged, and two patients were neurologically worse. Of the two patients who had deteriorated, one had a repeat CT scan of the head that revealed no change in the tumor size, and the other patient's CT scan demonstrated additional metastases relative to the number seen at the onset of treatment.

All four patients in the surgical group underwent gross total resection of their brain metastases in addition to

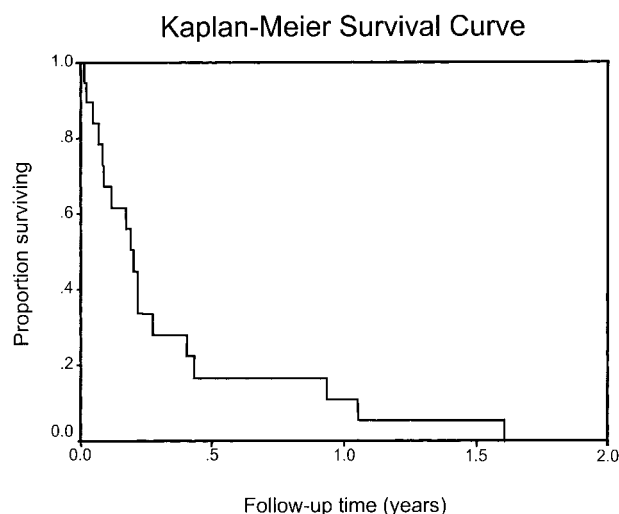
receiving 3000 cGy of whole-brain radiation and steroids. One patient from the surgical group left the country subsequent to neurological evaluation 1 month after surgery and was lost to follow-up thereafter. The remaining three patients lived for 22, 54, and 83 weeks (median, 54 weeks). At 1 month postoperatively, three patients showed improved neurological status, whereas that of the remaining patient was unchanged. Pre- and postoperative magnetic resonance images demonstrating gross total resection of a patient's metastatic lesion are shown in Fig. 2.

A comparison of the patients in treatment groups 1, 2, and 3 revealed mean ages of 58, 54, and 44 years, respectively. The majority of patients who had multiple metastases (9 of 11) were treated with radiation and steroids, but one patient with multiple lesions underwent surgery, and another such patient received no treatment. Systemic disease was present in all patients, although there was a trend toward less extensive disease in patients who underwent surgical resection.

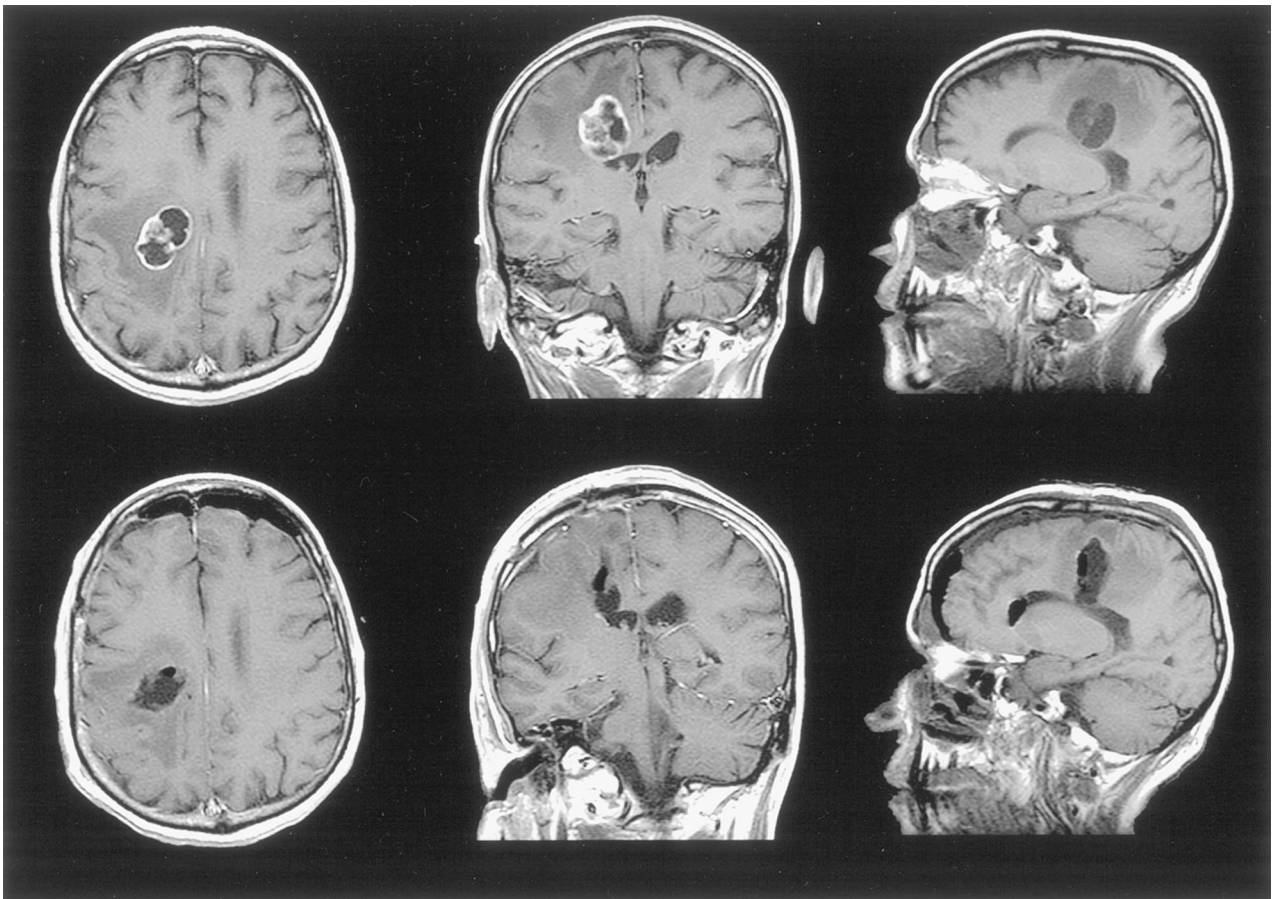
## DISCUSSION

Brain metastasis from gastric cancer is extremely rare. At M. D. Anderson, only 24 of 3320 patients with gastric cancer were found to have brain metastases during a 40-year period. Even this small number may be an overestimate of the incidence of brain metastases in this disease because of the unique pattern of referrals. In the United States, the overall survival rate for patients who are diagnosed with gastric cancer is quite low because the majority of gastric cancers are detected at an advanced stage. The overall 5-year survival rate is 17% and ranges from 2% (when associated with distant metastases) to 55% (when confined to the stomach).<sup>7</sup> Patients who do not receive either surgery or chemotherapy for their primary disease, presumably because of advanced disease status, have a median survival of 1–6 months, depending on the extent of their systemic disease.<sup>8,9</sup>

The location of the primary tumor and the distribution of metastases may provide some insight into the disease process. Studies from previous decades have reported that the majority of gastric tumors arise in the distal stomach,<sup>10</sup> although in the United States there has been a trend toward the occurrence of more proximal lesions during the past 20 years. Our series, which covered a 40-year period beginning in 1957, revealed that the majority of patients with brain metastases had primary lesions located in the proximal stomach. The relevance of our observing a high percentage of proximal stomach lesions is not clear; however, it has been reported that patients with tumors of the proximal stomach have a



**FIG. 1.** Kaplan-Meier estimate of survival for 19 patients diagnosed antemortem as having brain metastases from gastric carcinoma. Survival time was measured from the date of diagnosis of brain metastasis.



**FIG. 2.** Pre- and postoperative T1-weighted, gadolinium-enhanced magnetic resonance images of a patient who underwent resection of a right posterior frontal metastasis from gastric carcinoma. Preoperative axial, coronal, and sagittal images are shown in the *upper row*. Postoperative study (*lower row*) demonstrates gross total excision of the tumor. After surgery, the patient's left-sided weakness improved considerably.

poorer prognosis relative to patients with tumors located in the mid and distal stomach.<sup>10,11</sup>

Brain metastasis from gastric cancer is a late event in the disease's clinical course, and the low median survival after the diagnosis of brain metastasis is consistent with this.<sup>12</sup> All patients in our study had systemic cancer, either before death or at autopsy. It has previously been reported that the most common sites of metastases of gastric cancer are the liver, lungs, and bones.<sup>13</sup> Metastases to the liver were found in 42% of our patients, making it by far the most common single organ affected, followed by metastases to the lungs in 29% of patients. This distribution of metastases is consistent with a path of metastasis through the portal veins from the stomach to the liver, proceeding to the lungs, and then to the brain. However, bone metastases were found in 46% of our patients, including five patients who had vertebral body metastases. This finding suggests the existence of

an alternative route of metastasis that may bypass the portal circulation, possibly with hematogenous spreading of the tumors through Batson's vertebral plexus.

The evaluation of treatment did not provide encouraging data. Only four patients (three from the surgical group and one who received WBRT and steroids) displayed any improvement in their neurological condition after treatment of their brain metastases. The use of WBRT in conjunction with steroids did not increase survival relative to those patients who were treated with steroids alone. This response to radiotherapy is considerably poorer than the response seen with most other primary tumors that metastasize to the brain.<sup>4,14</sup>

The surgical group was the only group to experience a significant increase in survival relative to the other groups. Selection bias may have contributed to the increased survival of this group of patients. The small sample size here precludes a multivariate analysis; how-

ever, it is likely that the younger mean age and less extensive systemic disease seen in the patients who underwent surgery played a role in their improved outcome.

In patients with brain metastases from gastric carcinoma, it appears that no currently available treatment regimen is likely to produce long-term survival or yield a greatly improved neurological status. We must, therefore, conclude that current treatments are largely palliative.<sup>8,9</sup> Although selection bias of surgical candidates obscures the true value of surgical resection of metastatic lesions, when a patient's condition is favorable to surgery, this is likely to be the best palliation available.

**Acknowledgment:** The authors thank Dima Abi-Said, PhD, and Wei Ming Shi, MD, for assistance in preparing the figures.

### REFERENCES

1. World Health Organization. The World Health Report 1997. Available at <http://www.who.org/whr/1997/factse.htm>
2. Landis SH, Taylor M, Bolden S, Wingo PA. Cancer statistics, 1998. *CA Cancer J Clin* 1998;48:6–29.
3. Schein PS. Gastrointestinal cancer: a global perspective. In: Ahlgren JD, MacDonald JS, eds. *Gastrointestinal oncology*. Philadelphia: JB Lippincott, 1992:3–11.
4. Milani F, Mantero M. Radiotherapy for intracranial metastasis. *Tumori* 1979;65:401–5.
5. Saha S, Meyer M, Kremenz ET, Hoda S, Carter RD. Prognostic evaluation of intracranial metastasis in malignant melanoma. *Ann Surg Oncol* 1994;1:38–44.
6. Kaplan EL, Meier P. Nonparametric estimation from incomplete observations. *J Am Stat Assoc* 1958;53:457–81.
7. Albert C. Clinical aspects of gastric cancer. In: Rustgi AK, ed. *Gastrointestinal cancers: biology, diagnosis, and therapy*. Philadelphia: Lippincott-Raven, 1995:197–216.
8. Cairncross JG, Kim JH, Posner JB. Radiation therapy for brain metastases. *Ann Neurol* 1980;7:529–41.
9. Sawaya R, Ligon BL, Bindal AK, Hess KR. Surgical treatment of metastatic brain tumors. *J Neurooncol* 1996;27:269–77.
10. Breux JR, Bringaze W, Chappuis C, Cohn I. Adenocarcinoma of the stomach: a review of 35 years and 1,710 cases. *World J Surg* 1990;14:580–6.
11. Rhode H, Bauer P, Stutzer H, Heitman K. Gebbensleben and the German Gastric Cancer TNM Study Group: proximal compared to distal adenocarcinoma of the stomach: differences and consequences. *Br J Surg* 1991;78:1242–8.
12. Schiffer D. *Brain tumors: pathology and biological correlates*. Berlin: Springer-Verlag, 1993:498–505.
13. Warren S. Studies on tumor metastases: IV. Metastases of cancer of stomach. *N Engl J Med* 1933;209:825.
14. Cascino TL, Leavengood JM, Kemeny N, Posner JB. Brain metastases from colon cancer. *J Neurooncol* 1983;1:203–9.